Zebra or Horse Hooves: Case of Acute Pancreatitis in a Patient with Cholelithiasis on Hydrochlorothiazide

Amanda Jacubowsky, DO, Chandler Patton, DO, Timothy Graziano, DO, Michael Li, MD
Lehigh Valley Health Network, Allentown, PA

Introduction

- Acute pancreatitis is one of the most common conditions seen by gastroenterologists[1]
- Top Etiologies of Acute Pancreatitis[2]:
  1) Gallstones,
  2) Alcohol
  3) Medications
- Medical education provides learners with information to create broad differentials. Diagnoses that are less common have been termed ”zebras”

Project Aim

We aim to review how cognitive bias, including anchoring, can lead clinicians to inappropriately diagnose rare causes of common diseases like gallstone versus hydrochlorothiazide (HCTZ) induced acute pancreatitis.

Case Report

- 65-year-old with a past medical history of hypertension on HCTZ
- Patient Presentation: one day of epigastric abdominal pain radiating to the left flank, nausea, and emesis.
- Labs: lipase of 16,000, transaminitis, and leukocytosis.
- CT Abdomen: acute pancreatitis (left image) and L. hydronephrosis 2/2 obstructing 1.1 cm calcified ureteral calculus (right image)

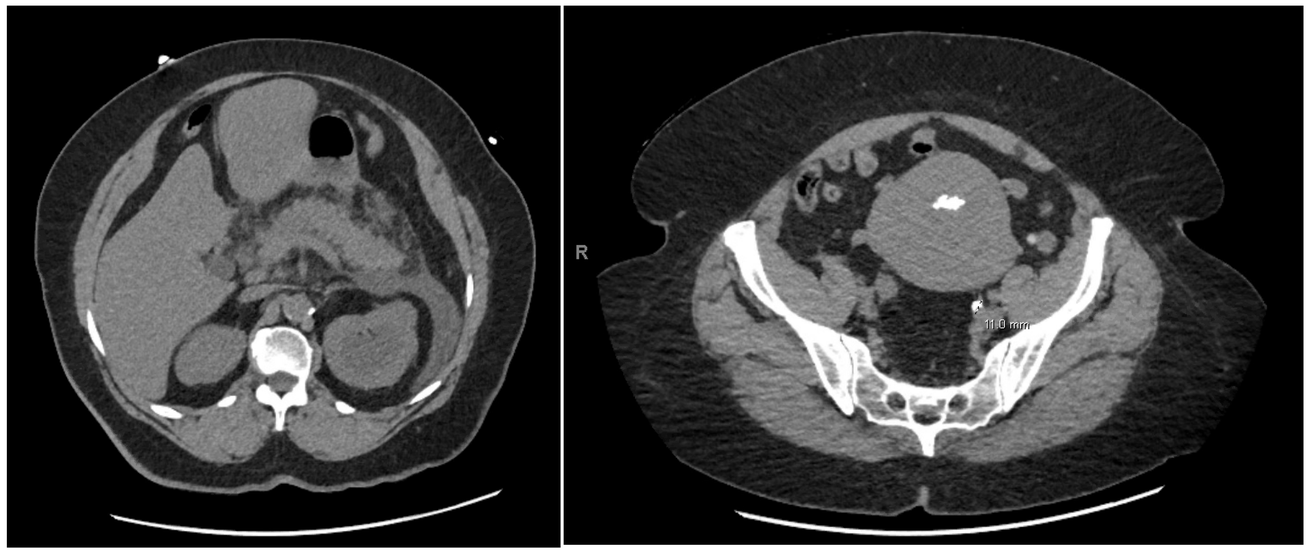

- Initial leading diagnosis: drug-induced acute pancreatitis secondary to HCTZ in a patient with calcium dysregulation
- Management: IVF, pain control, NPO for ureteral stent placement, d/c HCTZ, right upper quadrant ultrasound (which revealed cholelithiasis and diffuse hepatic steatosis)
- Final Diagnosis: gallstone pancreatitis
- Outcome: advanced diet successfully to low fat, patient to have outpatient laparoscopic cholecystectomy and continue a new antihypertensive regimen

Conclusion

- Cognitive bias can cause diagnosticians to misidentify "zebras among the horses”[3]
- In this case, the presumed etiology of a patient’s medical condition was influenced by anchoring as HCTZ is a very rare cause of pancreatitis
- Identifying types of bias in practice allows physicians to improve their overall clinical and diagnostic skills.

References

1) Lankisch PG, Apte M, Banks PA. Acute pancreatitis. *Lancet.* 2015;386(9988):85-96
2) Vinklerová, I., Procházka, M., Procházka, V., & Urbánek, K. (2010). Incidence, severity, and etiology of drug-induced acute pancreatitis. *Digestive Diseases and Sciences, 55* (10), 2977–2981. https://doi.org/10.1007/s10620-010-1277-3
3) Hirsch E. (2020). Horses and zebras: Probabilities, uncertainty, and cognitive bias in clinical diagnosis. *American Journal of Obstetrics and Gynecology, 222* (5), 469.e1–469.e3. https://doi.org/10.1016/j.ajog.2020.01.010
4) Jones, M. R., Hall, O. M., Kaye, A. M., & Kaye, A. D. (2015). Drug-induced acute pancreatitis: A review. *The Ochsner Journal, 15* (1), 45–51.