COVID-19 Induced Refractory Symptomatic Hypocalcemia in a Patient with Parathyroid Reimplantation

Jamey Moore, DO; Ho-Man Yeung, MD
Department of Internal Medicine, Temple University Hospital, Philadelphia, PA

Temple University Health System

Background

- Hypocalcemia in the setting of COVID-19 has been reported in prior case studies.
- Proposed mechanisms include direct viral interaction with ACE2 receptors in the parathyroid gland, viral chelation of calcium and inflammatory cytokines leading to PTH resistance[1].
- This case highlights a rare manifestation of COVID-19 induced hypocalcemia further complicated by the patient having a reimplanted parathyroid gland.

Patient Presentation

- A 73-year-old female with primary hyperparathyroidism requiring parathyroidectomy with gland reimplantation in the right forearm presented with a viral syndrome, found to have tetany and Chvostek's sign on physical exam.

Lab Results

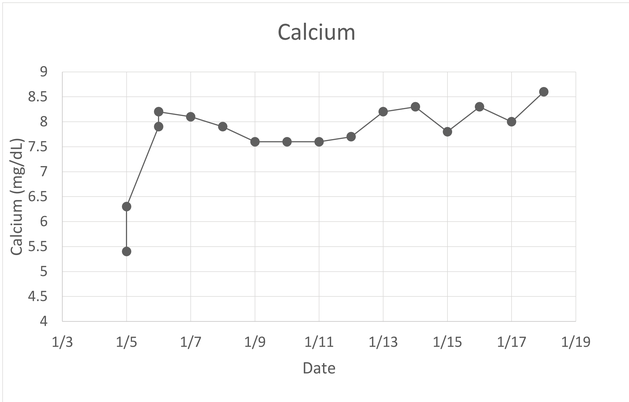

Figure 1: Calcium trend during hospital admission.

Lab Results

Lab	1/5/2022	1/9/2022	1/11/2022	1/16/2022
Calcium mg/dL	5.4	7.6	7.6	8.3
PTH pg/mL	242	487	74	-
Vitamin D-25 ng/mL	56	-	-	-
D-dimer (ng/mL)	1,283	762	734	660
CRP (mg/dL)	11	2.4	1.2	0.6

Table 1: Data showing significant work-up and trends revealing resolution of severe hypocalcemia and improvement in inflammatory markers during COVID-19 infection. Red values indicate sampling near gland (right arm).

Hospital Course

- Given the degree of hypocalcemia and symptoms, she was admitted to the ICU for IV calcium and COVID specific therapy.
- Tetany resolved after 9g calcium repletion, and she was transferred to the medical floor with an ionized calcium of 0.83 mmol/L.
- On hospital day 3, repeat ionized calcium was 0.78 mmol/L despite ongoing repletion. A repeat PTH level remained high at 487 pg/mL, suggesting ongoing PTH interference in the setting of COVID-19.
- Given the refractory nature of the hypocalcemia and prior parathyroid reimplantation, a PTH was obtained from the left arm which was normal.
- This indicated an appropriate PTH response from the reimplanted gland, and that ongoing hypocalcemia may be due to insufficient PTH function to maintain systemic calcium levels or a peripheral interference with PTH itself.
- With continued calcium supplementation and treatment of COVID-19 resulting in significantly reduced inflammatory markers from admission, she was discharged on oral calcium supplementation with endocrinology follow up.

Discussion

- Acute hypocalcemia strongly correlates with a profound inflammatory response in COVID-19 patients.
- This patient had a high PTH sampled near the reimplanted parathyroid gland, but a normal PTH distal from the reimplanted gland.
- This finding corroborates the hypothesis that there is a systemic interaction between circulating cytokines and PTH.
- Given there was release of PTH from the parathyroid gland, it seems less likely that there is a direct interaction between viral particles and PTH release from the parathyroid gland.
- This case is a unique circumstance and represents an ideal study model where PTH can be sampled peripherally near the parathyroid gland and this ease could aid in the process of determining the etiology of hypocalcemia in COVID-19.

References

1. di Filippo, L., Doga, M., Frara, S., & Giustina, A. (2022). Hypocalcemia in COVID-19: Prevalence, clinical significance and therapeutic implications. Reviews in endocrine & metabolic disorders, 23(2), 299–308. https://doi.org/10.1007/s11154-021-09655-z

Contact

jamey.moore@tuhs.temple.edu