# Not So SRAD: A Case Report on Spontaneous Renal Artery Dissection

Vanessa Hwu MS-IV[1] William Ghaul DO[2]

[1]Department of Internal Medicine, Lehigh Valley Health Network, Allentown, PA

## Introduction

- Spontaneous renal artery dissection is a rare condition that has been associated with atherosclerosis, hypertension, and connective tissue disease.
- Symptoms are relatively non-specific and include flank pain and hematuria.
- Often a diagnosis of exclusion, different imaging modalities such as abdominal ultrasound and CT angiography can help uncover a diagnosis.

## Case

- 50-year-old male presented to the ED complaining of R-sided abdominal pain with Kanofsky JA, Lepor H. Spontaneous renal artery dissection. *Rev Urol.* 2007;9(3):156-160
- Jiang J, Li L, Liu Y, Ren J, Su Q, Hu S, Ding X. Endovascular treatment of spontaneous renal artery dissection. J Vasc Surg. 2009;70(6): 1889-1895.radiation to his groin.
- History significant for laparoscopic Heller myotomy and fundoplication 13 days prior.
- Visiting as a commercial pilot from South Africa.
- CTAP revealed thrombosis of the right renal artery branch and infarction of the posterior medial right kidney.
- Admitted to hospital medicine for management.

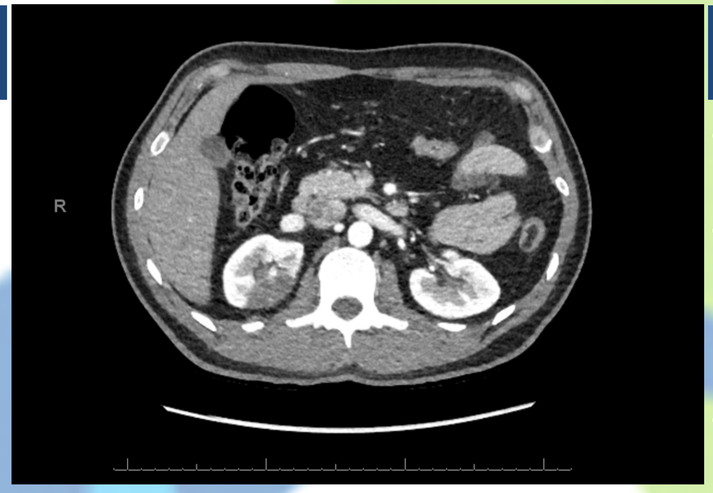


**•Figure 1: CTAP showing posterior infarction of R kidney.**

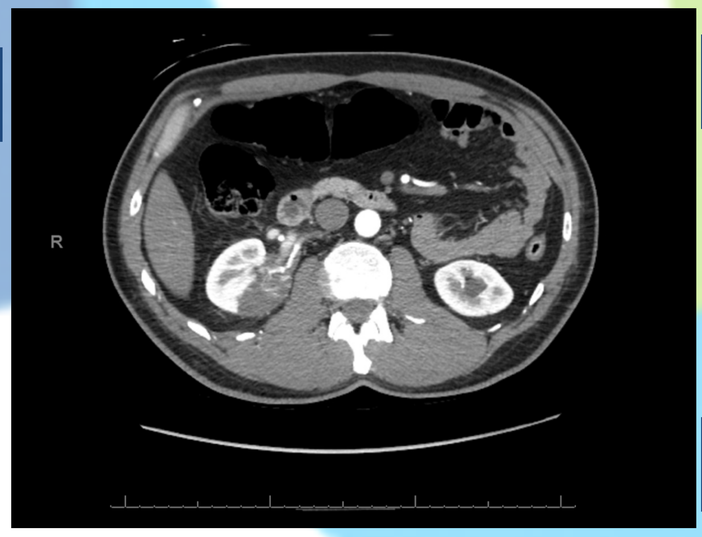


**•Figure 2: CT angiography showing dissection of R renal artery and posterior infarction of R kidney.**

## Results

- Vascular surgery, hematology, and nephronlogy were consulted.
- Given his recent surgery, CT angiography was ordered which showed a focal dissection involving the posterior branch of the right main renal artery with multiplee renal infarcts.
- Vascular surgery recommended medical management with daily aspirin and strict blood pressure control.
- Repeat renal artery duplex ordered for 2-3 months time.
- Discharged home on hospital day 3 to South Africa.

## Conclusion

- Most cases of SRAD occur in patients with previous risk factors such as hypertension, connective tissue disease, etc.
- Extensive coagulopathy work-up yielded limited results.
- Diagnosis made with CTA imaging.
- Awareness of this condition and early imaging is vital ofr establishing a diagnosis.

## References

- Kanofsky JA, Lepor H. Spontaneous renal artery dissection. *Rev Urol.* 2007;9(3):156-160
- Jiang J, Li L, Liu Y, Ren J, Su Q, Hu S, Ding X. Endovascular treatment of spontaneous renal artery dissection. J Vasc Surg. 2009;70(6): 1889-1895.

Lehigh Valley Health Network