Paradox of LAAO device: Stroke preventor or stroke culprit?

Hetal Boricha MD, Sourabh Khatri MD, Anjana Chandrasekhara Pillai, MD

Introduction

- Current guidelines recommend consideration of Left Atrial Appendage Occlusion(LAAO) procedure in patients with atrial fibrillation with high thrombotic and bleeding risk
- We present a case of a gentleman who suffered an air embolic stroke during LAAO procedure.

Case presentation

- 66-year-old male with a history of atrial fibrillation for 18 months, CHADSVASc score of 4 and HAS-BLED score of 2, was undergoing LAAO device procedure as he was unable to afford warfarin.
- Air was noticed in his left ventricle which was aspirated. One hour after the procedure when sedation weaned off, the patient noticed weakness in his left sided upper and lower extremity

Hospital course

- Magnetic resolution image (MRI) confirmed air in the right middle cerebral artery. The patient was urgently managed with hyperbaric oxygen for 6 hours.
- During oxygen therapy he developed seizure and had to be intubated for airway protection, prolonging his hospitalization. Patient's neurological symptoms almost resolved at discharge.

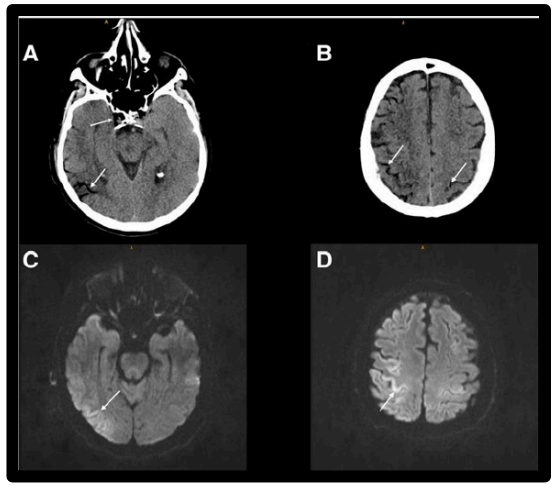

Fig 1 Magnetic resonance imaging of the brain

Discussion:

- Cerebral air emboli is rare, its occurrence is seen in iatrogenic situations like arterial catheterization, lung biopsy or cardiopulmonary bypass. Procedures like injecting agitated saline, defibrillator placement or transvenous pacemaker can introduce air into venous system which can travel to arterial side in presence of shunt
- Prompt identification and elimination of the source of air emboli is necessary. The patient must be placed in a Trendelenburg position to prevent the emboli from traveling into the brain. The right lateral decubitus position helps trapping the air in the right atrium and ventricle limiting it to the venous side
- An ischemic brain infarct requires treatment with hyperbaric oxygen. There must be no delay in treatment even in the absence of radiologic evidence. 100% oxygen displaces the room air emboli which contains more than 70% of nitrous oxide
- Prognosis is good if prompt treatment is initiated, 42% patients go home with neurological deficits. Poor prognosis and mortality are highly likely if oxygen therapy is delayed.

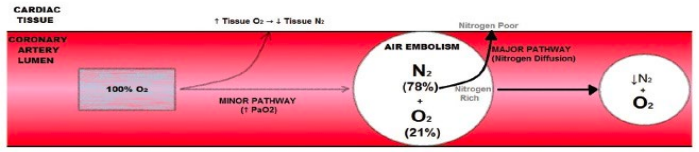

Figure 2. 100% oxygen (O_2) increases the partial pressure of O_2 in the blood, leading to both a decrease in the nitrogen (N_2) concentration of the coronary tissue (Minor Pathway), and the diffusion of N_2 from the N_2-rich air embolus to the N_2-poor tissue (Major Pathway); consequently, the embolus shrinks.

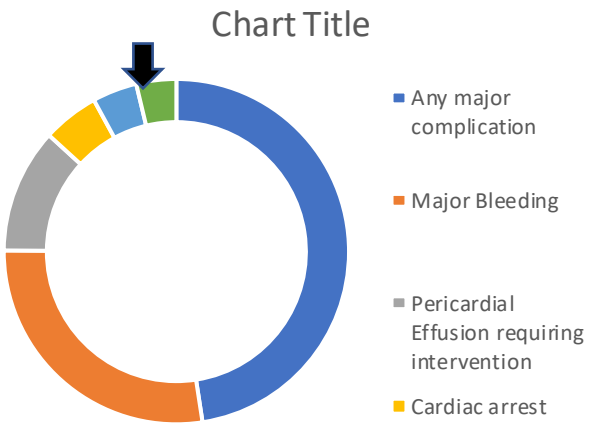

Graphical representation of adverse events with LAAO device

Learning points

- Cerebral air embolism is not usually associated with left atrial occlusion device procedure
- EWOLUTION registry with prospective data for 1021 patients showed only 3 cases of periprocedural air embolism
- Hyperbaric oxygen therapy is the mainstay and must be initiated at the earliest.