Calciphylaxis In Non-Uremic Patients, Unexpected And Easily Overlooked

Bernard Shalit, MD; Mark Biedka, DO; Ibrahim Ghobrial, MD, FACP
University of Pittsburgh Medical Center Mercy

BACKGROUND:

- Calciphylaxis is typically associated with advanced, dialysis-requiring chronic kidney disease.
- It presents as nonhealing, painful, ulcerative nodules, black eschars, and satellite purpura resulting from calcification, fibrosis, and thrombosis of the dermo-hypodermic arterioles.
- The condition is increasingly recognized in patients without advanced kidney disease, hence the term non-uremic calciphylaxis.
- Calciphylaxis carries notable mortality primarily due to sepsis. Early recognition and attention to metabolic risk factors is crucial because current treatment modalities are neither evidence-based nor very effective.

CASE REPORT:

This patient is a 62-year-old Caucasian male with HTN, HLD, uncontrolled T2DM (HbA1c 11%), CAD, chronic systolic and diastolic heart failure s/p ICD, as well as PVD s/p bilateral revascularization that presented to the ED from an outside facility with acute on chronic right lateral ankle wound. Prior skin biopsy was suggestive of pyoderma gangrenosum, and he was treated with prednisone, infliximab, and cyclosporine without significant improvement.

Clinical Findings:

Examination showed a large wound on the right lateral malleolus measuring approximately 2 x 2 cm with black eschar, foul-smelling scant purulent drainage, and significant tenderness with surrounding purpura and palpable peripheral pulses bilaterally. Doppler studies and angiography revealed occlusion of both the anterior and posterior tibial arteries with distal reconstitution of flow.

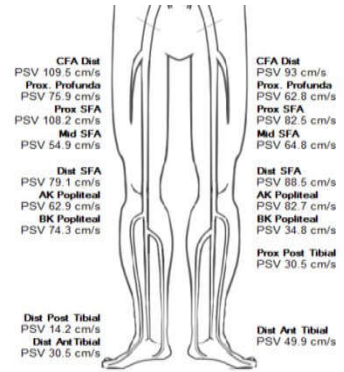

Figure 2. Duplex Scan, Lower Extremity Arteries show an occlusion of the anterior tibial artery at the ankle level, with reconstitution of low, monophasic flow just distal to the occlusion. Abnormal, monophasic waveforms are noted in the posterior tibial artery at the ankle level, suggestive of a proximal occlusion or stenosis.

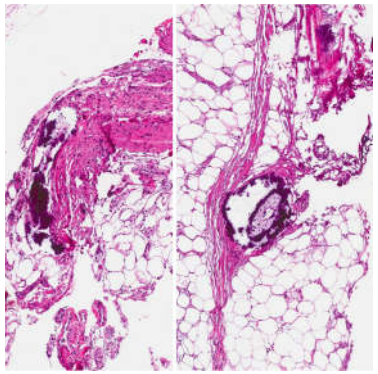

Figure 3. Dermal vascular occlusion and calcium deposition within the walls of large veins and the surrounding adipose tissue.

Figure 4. Panel of four images (A-D) demonstrate large ulcerated, painful lesion superior to the right lateral malleolus with overlying well-adhered eschar. Image E shows MRI of the right lower extremity demonstrating soft tissue erosion without bony involvement at the level of the lateral malleolus.

DISCUSSION:

- Calciphylaxis is a devastating condition with rapid progression to ischemic necrosis and sepsis with mortality quoted as high as 50% in the literature.
- Calciphylaxis should be considered while evaluating skin lesions in patients with predisposing conditions even in the absence of end-stage kidney disease and renal transplantation.
- Skin biopsy is diagnostic but can be omitted in typical cases due to the potential for pathergy.
- Pathology: dermo-hypodermal arteriolar calcification, subintimal fibrosis, and thrombotic occlusion; not to be confused with pyoderma gangrenosum, which has a neutrophilic infiltrate.
- Treatment: Address metabolic abnormalities (PTH, vitamin D, glucose, etc.); experimental therapies include sodium thiosulfate, leg revascularization, low-density lipoprotein apheresis, double-filtration rheopheresis.
- In addition to comprehensive modification of vascular disease risk factors, treatment involves a multidisciplinary approach that emphasizes empiric treatment of sepsis and excellent wound care which usually necessitates surgical consultation.

CONCLUSION:

- Calciphylaxis from non-uremic causes generates a significant mortality risk, primarily due to sepsis.
- Multidisciplinary coordination between internal medicine and surgical colleagues is paramount.
- Treatment focuses on correction of metabolic risk factors; experimental therapies targeting vascular growth factors and surgical intervention do not yet have data to support their routine clinical use.

REFERENCES:

- Nigwekar SU, Wolf M, Sterns RH, Hix JK. Calciphylaxis from nonuremic causes: a systematic review. Clin J Am Soc Nephrol. 2008 Jul;3(4):1139-43. doi: 10.2215/CJN.00530108. Epub 2008 Apr 16. PMID: 18417747; PMCID: PMC2440281.
- Declue C, Chinnakotla B, Gardner M J (May 13, 2021) Non-Uremic Calciphylaxis: An Unexpected Complication With Recombinant Human Parathyroid Hormone. Cureus 13(5): e15014. doi:10.7759/cureus.15014