# Pseudo thrombotic microangiopathy- differentiating between TMA and TTP

Shah, Shivani MD[1], Bhagavatula, Rama MD[2]

[1] Department of Medicine; [2]Division of Hematology and Cellular Therapy, Allegheny Health Network, Pittsburgh, PA

Allegheny Health Network

## Introduction

- Pseudo thrombotic microangiopathy (pseudo- TMA) is a relatively uncommon pathology in severely Vitamin B12 deficient patients and can present with microangiopathic hemolytic anemia (MAHA), thrombocytopenia and schistocytosis
- The prevalence of Vitamin B12 deficiency is 5-15%, and approximately 2.5% of cases present with pseudo – TMA.
- These cases can often masquerade as more serious conditions such as thrombotic thrombocytopenic purpura (TTP) leading to the use of plasma product therapy when not truly indicated.

## Case Presentation

| | Case 1 | Case 2 |
|---|---|---|
| **Age/Gender** | 52/Female | 33/Female |
| **Pertinent history** | Alcoholic cirrhosis | Iron deficiency anemia on iron supplementation |
| **Presenting symptoms** | Lower extremity and abdominal pain, cough, shortness of breath, lightheadedness | One week history of palpitations |
| **CBC** | Hb 6.3 g/dL<br>MCV 94.3 fL<br>WBC 2.97 k/mcL<br>Platelets 83 k/mcL | Hb 3.1 g/dL<br>MCV 125.7 fL<br>WBC 3.22 k/mcL<br>Platelets 70 k/mcL. |
| **Hemolysis parameters and Coombs test** | Haptoglobin <10 mg/dL<br>LDH 1958 U/L<br>Coombs test negative | Haptoglobin <10 mg/dL<br>LDH 1902 U/L<br>Coombs test negative |
| **RCI index** | 0.55, indicating hypo-proliferation | 0.36, indicating hypo-proliferation |
| **B12 levels** | <150 pg/mL | <150 pg/mL |
| **Peripheral smear** | Rare schistocytes | Slight schistocytosis and hyper-segmented neutrophils |
| **Methylmalonic acid** | --- | 26,683 nmol/L |
| **Workup** | -Parietal cell antibody positive<br>-Intrinsic factor antibody positive | -Intrinsic factor antibody positive |
| **Treatment** | -Daily 1000 mcg IM Vit B12 injections for a total of 7 days<br>-4 doses of weekly IM Vit B12 injections<br>-Subsequent monthly IM Vit B12 injections | -Daily 1000 Vit B12 IM injections while admitted<br>-4 doses of weekly Vit B12 IM injections<br>–Subsequent monthly IM Vit B12 injections |

- Both cases above had extensive workup for additional causes of pancytopenia that was negative: no nutritional deficiencies noted, no infectious causes.
- No evidence of DIC or TTP (normal ADAMTS13 activity),
- Both patients had antibodies indicative of pernicious anemia as the cause of their severe Vitamin B12 deficiency.

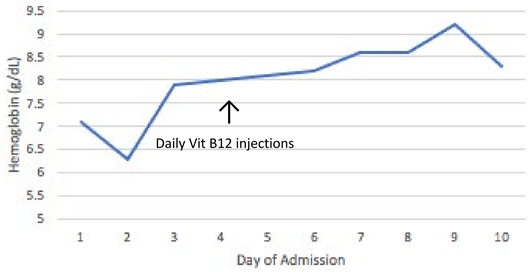


Figure 1: Case 1- hemoglobin trend with B12 repletion

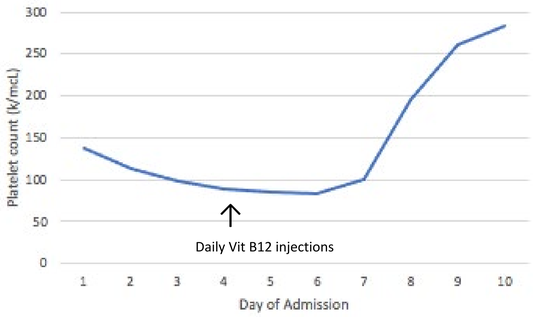


Figure 2: Case 1- platelet trend after with B12 repletion

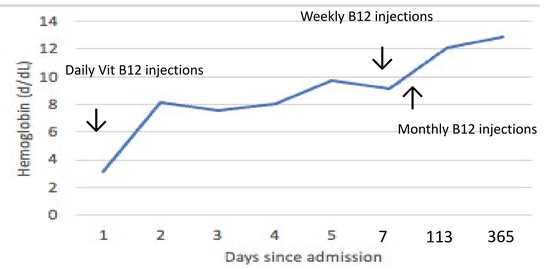


Figure 3: Case 2- hemoglobin trend with B12 repletion

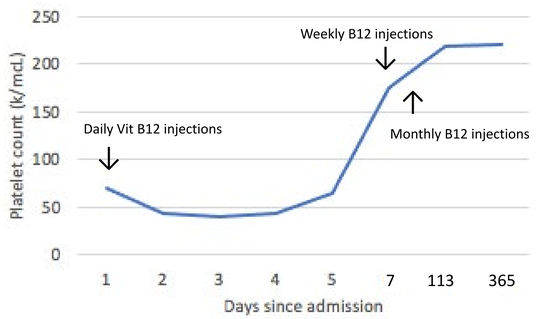


Figure 4: Case 2- platelet trend after with B12 repletion

## Discussion

- Pseudo-TMA can be difficult to recognize thus it is important to keep this disease process on the differential for patients with thrombocytopenia and hemolytic anemia.
- It can be even increasingly difficult to distinguish from thrombotic thrombocytopenic purpura (TTP) as both cases present with severe thrombocytopenia and anemia, severely elevated LDH, decreased haptoglobin, and severely low Vitamin B12.
- In prior reviews, approximately 40% of patients with pseudo-TMA were treated with plasmapheresis[1]. If diagnosed appropriately, one can avoid unnecessary treatment with plasmapheresis and increasing costs of healthcare.
- TTP can ruled out with a normal ADAMTS13 activity. A further difference to note is that reticulocyte index is low due to B12 deficiency in pseudo-TMA, which would be elevated in TMA.
- Disproportionately high LDH is a notable finding in with pseudo TMA secondary to vit B12 deficiency as well.

## Conclusion

- These cases emphasize the importance of early recognition of a condition that can be treated very easily and to avoid unnecessary and expensive plasma product therapy.

## References

1. Aung M Tun, Zin W Myint, Cristhiam Rojas Hernandez, Elizabeth Guevara, Kyaw Zin Thein, Thein Hlaing Oo; Vitamin B12 Deficiency-Related Pseudo-Thrombotic Microangiopathy Might be Misdiagnosed and Treated with Plasma Product Therapy: Review of the Literature and Analysis of the Reported Cases. *Blood* 2017; 130 (Supplement 1): 5576
2. Fahmawi Y, Campos Y, Khushman M, Alkharabsheh O, Manne A, Zubair H, Haleema S, Polski J, Bessette S. Vitamin B12 deficiency presenting as pseudo-thrombotic microangiopathy: a case report and literature review. Clin Pharmacol. 2019 Aug 27;11:127-131.