Isolated Cholestatic Liver Injury? Consider Metastatic Liver Injury

Alexis Espinal, BS[1], Jonathan Li, MD[2], Rawal Rachna, MD[3]

[1]University of Pittsburgh School of Medicine, Pittsburgh, PA, [2]Combined Internal Medicine-Pediatrics Residency Program, UPMC, Pittsburgh, PA, [3]Department of General Internal Medicine, UPMC, Pittsburgh, PA

Learning Objectives

- To recognize an uncommon clinical presentation of metastatic small cell lung cancer (SCLC) and general disease course.
- To recognize differences between modalities of imaging available for evaluating hepatobiliary disease.
- To recognize availability bias when encountering a common illness script of abdominal pain and abnormal LFTs.

Case Presentation

71 year-old female with 30-pack-year smoking history and hypothyroidism presenting for one week of severe, stabbing, intermittent right upper quadrant pain with one month of decreased appetite. Pain is not associated with eating or stooling. ROS negative for fevers/chills, nausea, vomiting, diarrhea, constipation, or B symptoms.

Hospital Course

Notable Labs

- CMP: ALT 64, AST 162, Alk Phos 916, Tbili 5.0, Cr 2.0
- CBC: WBC 10.9 (normal differential), Hgb 16.4, PLT 394
- Lactate 2.9
- CRP 15.7, ESR 21
- Negative blood and urine cultures
- Negative hepatitis and HIV serologies
- Negative AFP, CEA, CA 19-9

Physical Exam

- Vitals: 37C, 128 bpm, 119/89 mm Hg, and 97% room air
- Abdomen: RUQ tenderness, + Murphy Sign, no hepatomegaly

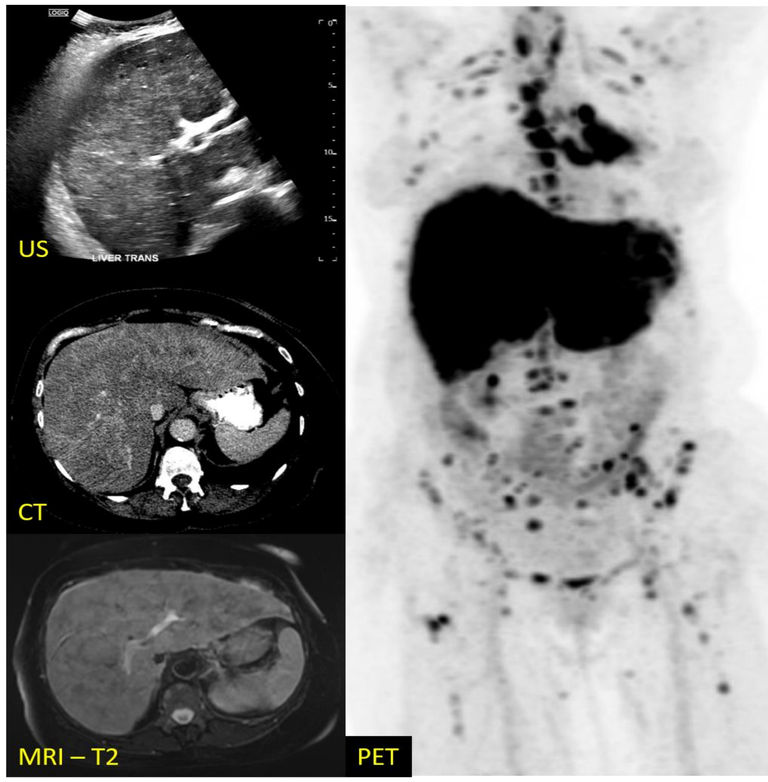

Figure 1: Hepatic imaging with US, CT, MRI, and PET

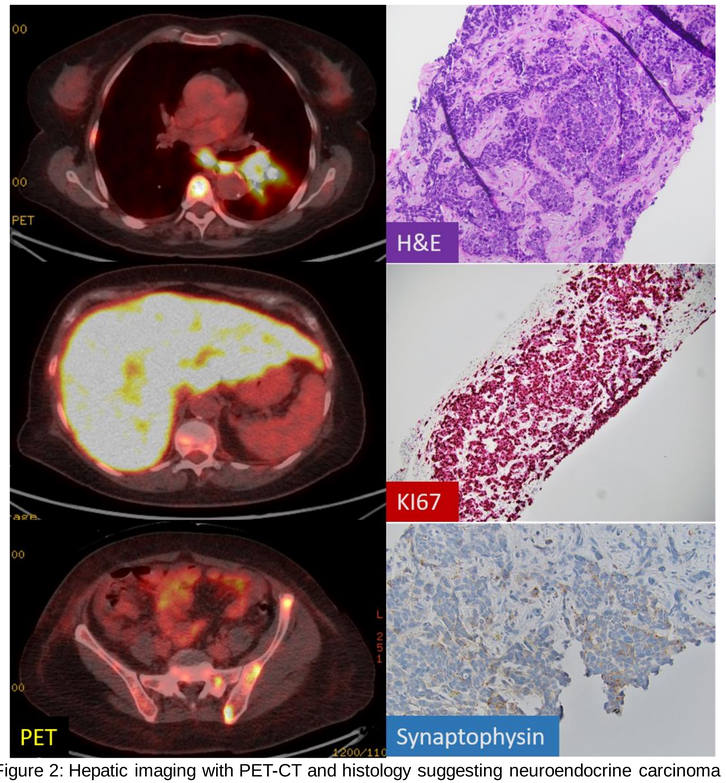

Figure 2: Hepatic imaging with PET-CT and histology suggesting neuroendocrine carcinoma

Hospital Course

Imaging

Abdominal U/S: Evidence of hepatic fibrosis (Fig 1)
CT Abdomen and Pelvis: Heterogenous liver parenchyma with left sided focal hypoattenuation concerning for infiltrative process (Fig 1)
CT Angiogram Chest: Bulky mediastinal adenopathy, bulky left hilar lymphadenopathy with left bronchial narrowing- cannot exclude left hilar mass.
MRI: Heterogenous liver parenchyma suggesting hepatic fibrosis and/or infiltrative process (Fig 1)
FDG PET Imaging: Markedly enlarged liver with diffuse hepatic metastasis, multiple osseous metastasis, and left hilar lung mass with significant mediastinal lymphadenopathy. (Fig 1 & 2)

Outcome

Given the histopathological changes (Fig 2) in combination with tumor phenotype indicating a poorly differentiated neuroendocrine carcinoma, our patient was ultimately diagnosed with primary SCLC.
Her ALP and T-bili doubled in 2 weeks and had 5 lbs of weight loss. Unfortunately, she rapidly declined and was transitioned to comfort

Conclusions

- Cholestatic injury is not always due to a local process, beware of availability bias.
- ~15% of all lung cancers are SCLC of which 60% present with metastatic disease, most commonly brain, liver, adrenals, bone/bone marrow.
- Rapid symptom onset ~ 8-12 weeks before presentation.
- Untreated, median survival is 2-4 months.
- A number of reports describe isolated cholestatic liver injury as the presenting sign of metastatic SCLC.
- Clinicians should have high suspicion for metastatic SCLC in patients with both a pulmonary mass and infiltrative liver disease.

References

- Basumallik N, Agarwal M. Small Cell Lung Cancer. [Updated 2022 Jul 12]. In: StatPearls [Internet]. Treasure Island (FL): StatPearls Publishing; 2022 Jan-.
- Khan, Z., et al. "Obstructive Jaundice Secondary to Intrahepatic Cholestasis by Diffuse Metastatic Liver Disease as the Initial Presentation of Small Cell Lung Cancer." B75. CASE REPORTS IN THORACIC ONCOLOGY VII. American Thoracic Society, 2018. A4141-A4141.
- Mishima S et al.: Diffuse Liver Metastasis of Small-Cell Lung Cancer Presenting as Acute Liver Failure and Diagnosed by Transjugular Liver Biopsy: A Rare Case in Whom Nodular Lesions Were Detected by Enhanced CT Examination. Case Rep Gastroenterol 2015;9:81-87. doi: 10.1159/000381140