# An unusual case of atrial flutter presenting as bradyarrhythmia

Yasmeen Mustafa, James Koch, Muhammad O. Hanif, Eric H Green

**Introduction**

Atrial flutter (AF) is one of most common abnormal cardiac rhythm characterized by tachyarrhythmias related to abnormal circular electrical pathways in the atrium with an isolated atrial depolarization of approximately 250-300 beats/min and ventricular rate of almost 150 beats/min. We describe a case of AF as bradyarrhythmia rather than the usual tachyarrhythmia requiring a permanent pacemaker (PM).

**Case Report**

A 68-year-old male with past medical history of alcohol abuse, ependymoma of the thoracic spine with surgery in 1991, chronic residual bilateral leg weakness along with sensory loss, with history of self-catheterization not on any home medications presented to the hospital with 3 episodes of syncope (complete black outs) within a 2-day period. In the emergency department his heart rate (HR) was between 30s to 40s bpm (beats/minute). EKG was done which was suggestive of new onset AF with marked bradycardia with a HR of 39 bpm and right axis deviation with left anterior fascicular block (Bifascicular block). His echocardiogram showed normal ejection fraction of 60-65%, mild tricuspid regurgitation with pulmonary artery systolic pressure of 49 mmhg. He was later moved to the step-down unit with his HR persistently staying in 30-40s bpm. Patient was taken for right heart and left heart catheterization along with temporary PM insertion by the cardiologist. No structural heart disease was found. He had a successful placement of temporary PM and was later moved to Intensive care unit with anticoagulation on heparin drip after cardiac catheterization. He was later scheduled for the ablation and permanent PM insertion by the Electrophysiologist. He had a successful radiofrequency ablation (RFA) of the typical counterclockwise cavo-tricuspid isthmus (CTI) dependent flutter which replaced the AF and had successful implantation of dual chamber PM. He was later discharged in stable condition with outpatient follow up with Cardiology.

.

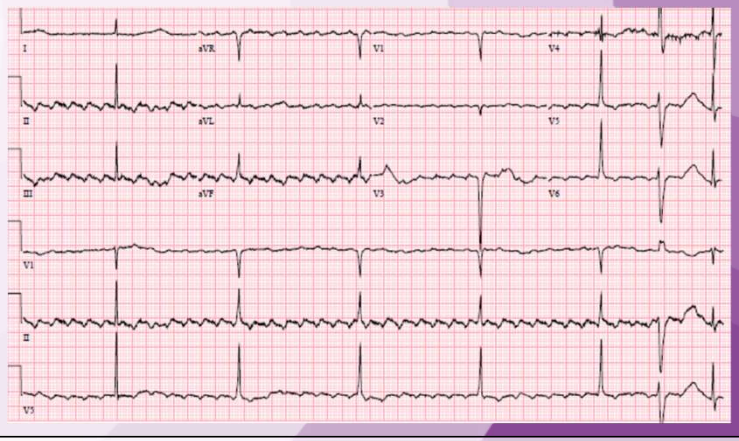


**Discussion**

Bradyarrhythmia such as AF with slow ventricular response (SVR) is often seen in patients with AV nodal-blocking medications, however other causes include electrolyte abnormalities, hypothermia and intrinsic conduction system diseases. Varying amounts of block in the AV node can lead to varying conduction ratios in AF and this can be life-threatening due to hemodynamic instability related to lower ventricular conduction. In this case, catheterization and echocardiography were first completed ruling out structural disease. RFA of the CTI is curative in these cases. When approaching bradyarrhythmia such as AF with SVR, clinicians must consider a broad differential of extrinsic and intrinsic etiologies.

Trinity Health Mid-Atlantic | Mercy Catholic Medical Center

**Literature cited**

1.Crees Z, Fritz C, Huedebert A, Noe J, Rengarajan A, Wang X. The Washington Manual of Medical Therapeutics Paperback. Philadelphia: Wolters Kluwer; 2019.

2.Unusual Presentation of Atrial Flutter With Slow Ventricular Response. Cureus. 2021;13:e15801-e15801.