Cavitary Lung Disease in COVID-19

Syeda Fatima Hassan MD[1], *Nathaniel Rosal DO[1], Rameesha Mehreen MD[1], Richard Friedenheim MD[2]*

1. Department of Internal Medicine, Abington Jefferson Health, Abington, PA

2. Department of Pulmonary and Critical Care, Abington Jefferson Health, Abington, PA

Introduction

Cavitary lung disease has been described in many different pathologies, namely fungal, mycobacterial, and autoimmune diseases. After roughly one year since the onset of the COVID-19 pandemic, literature on cavitary lung disease in patients with the SARS-COV2 virus is emerging.

Imaging

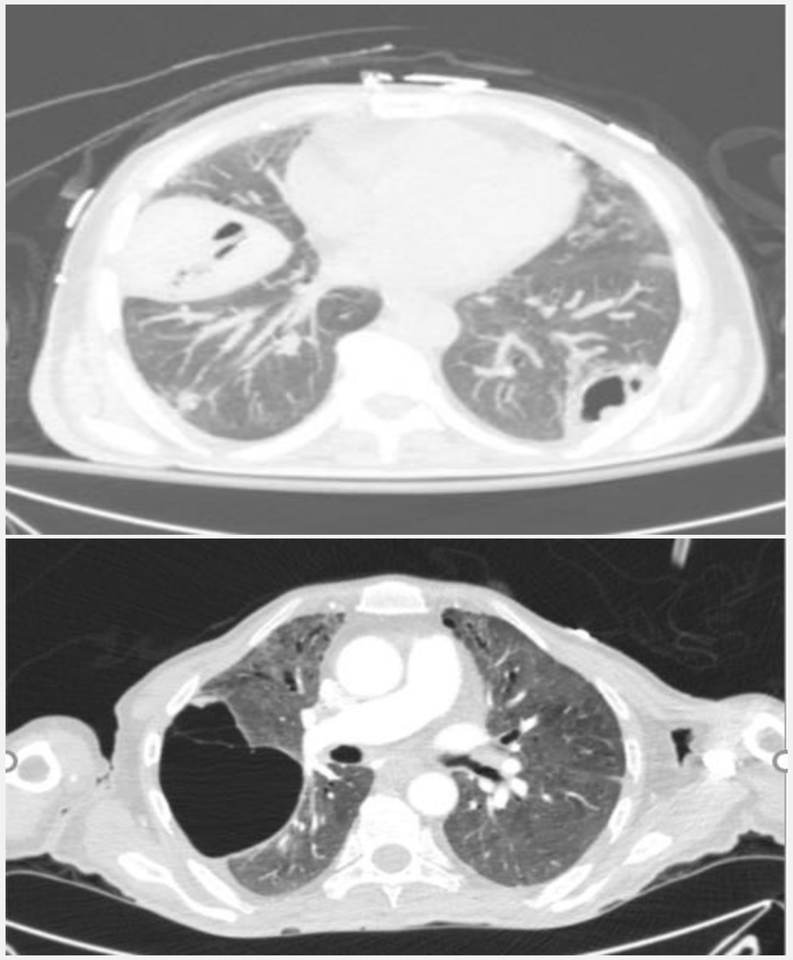

Follow Us on Instagram!

To find out more about our residency program, scan this QR code!

@abingtonjeffersonIM

Case

A 63-year-old male with no significant past medical history presented with a chief complaint of shortness of breath in the setting of a known COVID-19 infection. After nine days of self-quarantining, the patient presented to the hospital with minimal improvement in symptoms. The patient was intubated for refractory hypoxia, though ultimately required extracorporeal membrane oxygenation (ECMO). After one month on ECMO, the patient was found to have a cavitary lesion of the left middle lung. Throughout his hospitalization, he was treated with Remdeisivir, dexamethosone for COVID-19, as well as broad spectrum antimicrobials vancomycin, pipercillin/tazobactam, and anidulofungin. Blood, sputum, and bronchoalveolar lavage cultures were obtained for bacterial, fungal, acid fast, and cryptococcus, all of which revealed no etiology. Aspergillus Galactomannan antigen, HIV-1 p24 antigen and HIV-1/HIV-2 antibody, cryptococcus antigen, were not detected in the blood. SARS-CoV 2 Nucleic acid amplification test however, was persistently positive. His antimicrobial regimen was discontinued after sufficient empiric coverage. Subsequent CT scans of the chest were significant for multiple new cavitary lesions. Despite these findings, the patient was successfully decannulated from ECMO, though ultimately required tracheostomy for weaning of mechanical ventilation and percutaneous endoscopic gastrostomy tube for nutrition before discharge to a skilled nursing and rehabilitation facility.

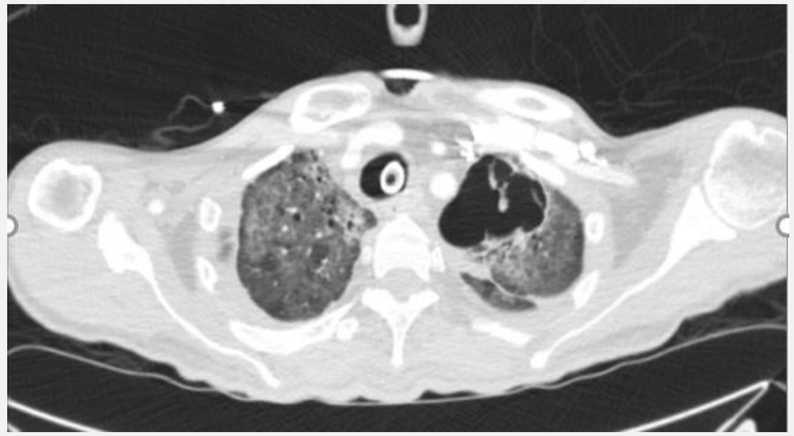

Discussion

Cavitary lung lesions may represent a late finding in COVID-19 pneumonitis though the mechanism of their development is still being investigated. Hypothesized mechanisms include specific inflammatory pathways, Micro infarctions, and/or intra-alveolar hemorrhage and necrosis of parenchymal cells .

Further studies and case reports may shed light on the long term effects of this finding in COVID-19 patients

Conclusion

COVID 19 pneumonitis should be a consideration in the differential diagnosis in patient with cavitory lesions in the lungs

References

1. Ackermann M, Verleden SE, Kuehnel M, Haverich A, Welte T, Laenger F, Vanstapel A, Werlein C, Stark H, Tzankov A, Li WW, Li VW, Mentzer SJ, Jonigk D. Pulmonary Vascular Endothelialitis, Thrombosis, and Angiogenesis in Covid-19. N Engl J Med. 2020 Jul 9;383(2):120-128. doi: 10.1056/NEJMoa2015432. Epub 2020 May 21. PMID: 32437596; PMCID: PMC7412750.
2. Selvaraj V, Dapaah-Afriyie K. Lung cavitation due to COVID-19 pneumonia. BMJ Case Rep. 2020 Jul 6;13(7):e237245. doi: 10.1136/bcr-2020-237245. PMID: 32636231; PMCID: PMC7358100.

Abington Jefferson Health