CT got your tongue? Non-convulsive status epilepticus causing isolated global aphasia

GL Lisius[1]

[1] University of Pittsburgh Medical Center Internal Medicine Residency, Pittsburgh, PA, USA

LEARNING OBJECTIVES

(1) Discuss the differential of acute aphasia.

(2) Describe key clinical findings and patient risk factors for non-convulsive status epilepticus (NCSE).

CASE PRESENTATION

- 73-year-old female teacher with Von Willebrand disease and treated non-Hodgkins lymphoma on ibrutinib presented with acute inability to speak.
- Onset at rest 1 hour prior. She was visibly frustrated, could not name objects, answer questions, or repeat words. She inconsistently followed commands.
- Home medications ibrutinib. No alcohol, or substances
- Afebrile. BP: 160s / 90s, HR: 80s.
- Exam: mixed expressive and receptive aphasia. Neurologic exam was otherwise normal.

LABS AND IMAGING

5.4	13.6	217

137	106	16	136
3.7	21	0.8	

UDS negative. TSH, LFTs normal.

Imaging:

CT head non-contrast with vague left frontal hypodensity

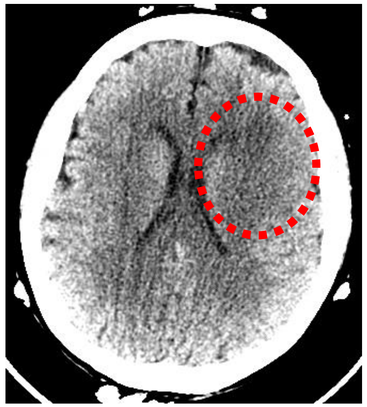

DIFFERENTIAL DIAGNOSIS and WORK-UP

Acute global aphasia differential	Reasoning	Evaluation
Acute ischemic stroke	Most common, Acuity. **Discordance:** global aphasia suggests large territory involvement, would expect other neuro findings	Brain MRI
Mass → Seizure	Hypodensity on CT. No prior seizure history	EEG
Infectious	Age, + immunosuppressed. No leukocytosis, fever.	LP
Toxic / metabolic	No electrolyte abnormalities, substances, culprit medications	UDS

HOSPITAL COURSE

- EEG → non-convulsive status epilepticus (NCSE)
  - Anti-epileptics → aphasia resolved
- Brain MRI → infiltrating left frontal lesion, crossed midline. Given her immunosuppression, diagnoses included CNS lymphoma, progressive multifocal leukoencephalopathy, or primary brain tumor.
- Lumbar puncture: unrevealing.
- Brain biopsy → glioblastoma

Her extensive disease limited surgical or chemotherapy options. She chose home hospice.

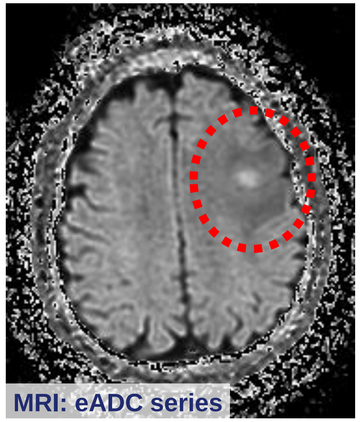

MRI: eADC series

ACUTE APHASIA

Location: A large region of the left hemisphere

Causes: Most common: Ischemic stroke, TIA

- Structural: hemorrhagic stroke, brain mass, tumor, or abscess
- Infectious: encephalitis
- Seizure or post-ictal
- Neurodegenerative diseases
- Migraine
- Traumatic brain injury

Speech therapy is crucial.

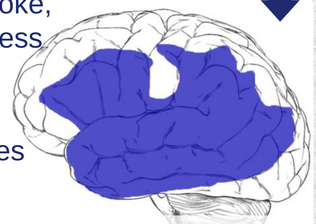

Language regions of the brain[3]

NONCONVULSIVE STATUS EPILEPTICUS

Epidemiology: 50% have a prior seizure disorder

Risk factors: CNS pathology,

- Toxic/metabolic encephalopathy
- Encephalitis
- Systemic illness
- After convulsive status
- Substances, meds:β-lactams,

Seizure on EEG[4]

Clinical findings:

- Coma, acute mental status or behavioral change including new psychosis
- Automatisms such as lip smacking, orofacial twitching, arm and hand stereotypic movements (44% specific)
- Repetitive eye movements or deviation (86% specific)

REFERENCES

1. Hillis AE. Aphasia: progress in the last quarter of a century. Neurology 2007; 69:200.
2. Rossetti AO, Schindler K, Sutter R, et al. Continuous vs Routine Electroencephalogram in Critically Ill Adults With Altered Consciousness and No Recent Seizure: A Multicenter Randomized Clinical Trial. JAMA Neurol 2020; 77:1225.
3. Image via Creative commons: Bertyhell. Aphasia regions, https://dx.doi.org.helicon.vuw.ac.nz/10.1093/brain/awt374 (2015). 4. Image via Creative commons: Der Lange. Spike and Wave Seizure. http://commons.wikimedia.org/w/index.php?title=File:Spike-waves.png