A Sarcoma to Make your Heart Stop: A Case of Refractory Ventricular Tachycardia Caused by Metastatic Sarcoma

Mina Shnoda, MD,[1] Deanna Huffman DO,[1] Michael Popeck, DO[2], Vijaya Sanikommu, MD[2], Rodney Wegner, MD[3], Veli Bakalov, MD[4], Shifeng Mao, MD[4], Larissa Greenberg, MD[4], Catherine Madden

[1] Department of Medicine; [2]Division of Cardiology; [3]Divison of Radiation Oncology; [4]Division of Medical Oncology, Allegheny Health Network, Pittsburgh, PA

Allegheny Health Network

Introduction

Cardiac tumors are increasing in incidence as patients with metastatic cancer have improved longevity. Cardiac metastases are most commonly silent and diagnosed post-mortem, but when symptomatic can present dramatically with symptoms of heart failure, arrhythmia or vascular obstruction. We describe the multidisciplinary approach to manage recurrent ventricular tachycardia (VT) arising from epicardial metastasis and mass effect on the left ventricle.

Case Presentation

- A 22-year-old male presented with intermittently dizzy and had multiple witnessed syncopal episodes.
- An EKG obtained during the episodes of VT showed monomorphic VT arising from the left ventricle. Chest x-ray showed innumerable lesions in bilateral lungs concerning for metastatic disease. A transthoracic echocardiogram was performed showing left ventricular ejection fraction of 45-49% with mild global hypokinesis and a large 3.5x2.5 cm echodense mass within the pericardial space abutting the left ventricle apical epicardium with no infiltrate beyond the epicardial layer.
- An excisional biopsy was performed of a prominent axillary lymph node, and the pathology returned as a poorly differentiated malignant neoplasm consistent with rhabdomyosarcoma (RMS), embryonal subtype. CTAP revealed the likely primary tumor as a large necrotic mass in the pelvis.
- The patient continued to have episodes of VT resulting in hemodynamic instability with failure to control with medical therapy.

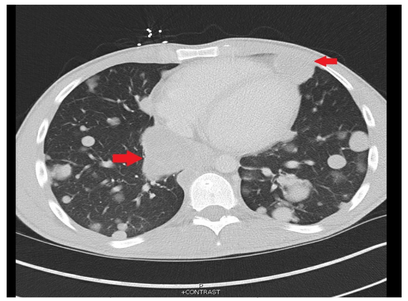

Figure 1. CT Chest with contrast showing masses causing mass effect on the heart

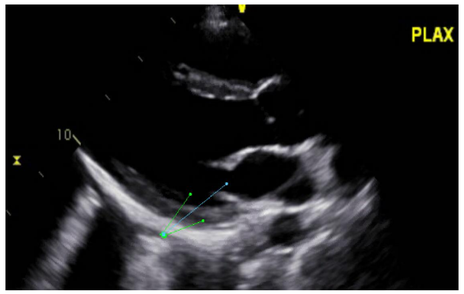

Figure 2. Transthoracic echocardiography images showing large echodense mass in the pericardial space abutting the LV apical epicardium. It does not appear to infiltrate beyond the epicardial layer.

Medical Decision Making

A multidisciplinary decision was made to pursue one radiation treatment for the mass located in front of the left ventricle to help with control of ventricular tachycardia. The approach was successful to control the VT and the patient was successfully transitioned to an oral regimen of amiodarone and a beta-blocker with no recurrence of his VT.

Table 1. Selected literature review of cases with cardiac metastatic disease and their management

Case Reference	Primary Tumor	Location of Cardiac Metastasis	Management	VT Outcome
Elijah H. Beaty,et al, (2014)[3]	Sarcoma	RV free wall	Amiodarone	Controlled
Dominguez-Perez L et al. (2012)[4]	Renal cell carcinoma	Anterior Septum of LV	Amiodarone	Controlled
Huang SH, et al. (2011)[5]	NK T-cell Lymphoma	Postero-lateral wall of LV	Amiodarone	Failed to control VT
Lanzillo T, et al. (2011)[6]	Renal cell carcinoma	Apex and Anterior wall of LV	Chemotherapy and Amiodarone	Controlled
Casella M et al. (2011)[7]	Gluteal Sarcoma	Anterior and lateral wall of LV	Radiofrequency ablation	Controlled

Conclusion

Although rarely reported in medical literature, patients with epicardial metastatic disease can develop ventricular tachycardia due to mass effect on the left ventricle. Our case supports the approach of using radiation therapy to alleviate the previously mentioned mass effect and manage recurrent VT resistant to medical therapy.

References

1. Domínguez-Pérez Laura, Arias Miguel A., Juliá-Calvo Justo, et al. Unusual Case of an Intramyocardial Tumor Presenting With a Ventricular Tachycardia. Circulation. 2012;125(25):3246-3249. doi:10.1161/CIRCULATIONAHA.111.068395
2. Li Y-Y, Wang H, Cui Y-D, Liu H-Y, Yang J-F. Sustained Ventricular Tachycardia Secondary to Cardiac Metastasis of Lung Cancer. Chin Med J (Engl). 2018;131(3):352-353. doi:10.4103/0366-6999.223842
3. Beaty EH, Ballany W, Trohman RG, Madias C. Ventricular Tachycardia Associated with Radiation-Induced Cardiac Sarcoma. Tex Heart Inst J. 2014;41(6):620-625. doi:10.14503/THIJ-13-3378
4. Domínguez-Pérez L, Arias MA, Juliá-Calvo J, et al. Unusual case of an intramyocardial tumor presenting with a ventricular tachycardia. Circulation. 2012;125(25):3246-3249. doi:10.1161/CIRCULATIONAHA.111.068395
5. Kosugi S, Tamura S, Sekiguchi M, et al. Extranodal Natural Killer/T-cell Lymphoma, Nasal Type Presenting with Myocardial Involvement and Severe Heart Failure. Los Angel. 2018;6(2):4.
6. Lanzillo T, Manganelli F, Rosato G, Rotondi F. Sustained ventricular tachycardia in renal cell carcinoma metastatic to anterior-apical wall of the left ventricle. EP Eur. 2011;13(11):1658-1658. doi:10.1093/europace/eur167
7. Casella M, Carbucicchio C, Dello Russo A, et al. Radiofrequency catheter ablation of life-threatening ventricular arrhythmias caused by left ventricular metastatic infiltration. Circ Arrhythm Electrophysiol. 2011;4(2):e7-10. doi:10.1161/CIRCEP.110.961193
8. Chemello D, Raupp-da-Rosa P, Telo G, Clausell N. Ventricular tachycardia associated with non-Hodgkin's lymphoma. Arq Bras Cardiol. 2011;97(6):e132-134. doi:10.1590/s0066-782x2011001500017
9. Tekbas E, Tekbas G, Islamoglu Y, et al. Unusual metastatic localization of osteosarcoma in a teenager with ventricular tachycardia. Am J Emerg Med. 2010;28(9):1059 e1-3. doi:10.1016/j.ajem.2010.01.021
10. Ibars S, Anguera I, Gusi G, et al. Myocardial metastases presenting as ventricular tachycardia. J Electrocardiol. 2007;40(4):365-367. doi:10.1016/j.jelectrocard.2006.11.011
11. Dorfman FK, Mesas CE, Cirenza C, de Paola AAV. Bidirectional ventricular tachycardia with alternating right and left bundle branch block morphology in a patient with metastatic cardiac tumors. J Cardiovasc Electrophysiol. 2006;17(7):784-785. doi:10.1111/j.1540-8167.2006.00409.x
12. Lim HE, Pak H-N, Jung HC, Kim JS, Shim WJ, Kim Y-H. Electrocardiographic manifestations of cardiac metastasis in lung cancer. Pacing Clin Electrophysiol PACE. 2006;29(9):1019-1021. doi:10.1111/j.1540-8159.2006.00480.x
13. Jaster M, Gutberlet M, Dinkloh N, Schneider P, Schultheiss H-P, Morguet AJ. Ventricular tachycardia indicating cardiac involvement in metastatic leiomyosarcoma. J Clin Oncol Off J Am Soc Clin Oncol. 2006;24(21):3502-3504. doi:10.1200/JCO.2005.04.9171
14. Cho J-G, Ahn Y-K, Cho S-H, et al. A case of secondary myocardial lymphoma presenting with ventricular tachycardia. J Korean Med Sci. 2002;17(4):549-551.
15. Manojkumar R, Sharma A, Grover A. Secondary lymphoma of the heart presenting as recurrent syncope. Indian Heart J. 2001;53(2):221-223.
16. Leak D. Amiodarone for control of recurrent ventricular tachycardia secondary to cardiac metastasis. Tex Heart Inst J. 1998;25(3):198-200.
17. Sheldon R, Isaac D. Metastatic Melanoma to the Heart Presenting with Ventricular Tachycardia. Chest. 1991;99(5):1296-1298. doi:10.1378/chest.99.5.1296
18. Bussani R, De-Giorgio F, Abbate A, Silvestri F. Cardiac metastases. J Clin Pathol. 2007;60(1):27-34. doi:10.1136/jcp.2005.035105
19. Heidenreich PA, Kapoor JR. Radiation induced heart disease. Heart. 2009;95(3):252-258. doi:10.1136/hrt.2008.149088