Ultra Low Dose PET/MRI Imaging of Crohn's Disease Using a Novel Deep Learning Reconstruction Method

[1,2]Christian J. Park, DO♦ [2,3]Wei-Jie L. Chen, MS♦ [2]Ali Pirasteh, MD♦ [2]Scott B Perlman, MD ♦ [2]David H Kim, MD♦ [2]Jessica B Robbins, MD♦ [2]Alan B McMillan, PhD

[1]Department of Radiology, Penn State Health Milton S. Hershey Medical Center, Hershey, PA 17036 ♦ [2]Department of Radiology, University of Wisconsin School of Medicine and Public Health♦ [3]Department of Electrical and Computer Engineering, University of Wisconsin Madison, WI 53706

ABSTRACT: Background: An obstacle to incorporating positron emission tomography (PET) as an adjunct for imaging patients with Crohn disease (CD) is the radiation exposure from the injected ^{18}F-fluorodeoxyglucose (FDG). Utilization of a deep learning enhancement (DLE) algorithm can assist with generation of PET images from fewer counts and less data, hence mimicking a lower-injected dose. This study investigated the feasibility of ultra-low-dose PET/MR by comparing low dose PET images generated by a DLE algorithm to those generated by a standard of care (SOC) conventional reconstruction algorithm. **Methods:** Twenty subjects with known CD underwent simultaneous PET/MRI after intravenous administration of approximately 185 MBq of FDG (50% of a conventional clinical dose). DLE utilized a fully convolutional neural U-net and leave-one-out cross validation. Five image sets were generated from the list mode PET data: (1) SOC images from a 5-minute study, (2) Low dose (LD) images obtained from 1/5th sampling of the SOC counts (approximately 37 MBq), (3) LD images using a DLE approach trained on PET data ($DLELD_{PET}$), (4) LD images using a DLE approach trained on PET and MR data ($DLELD_{PET-MR}$), (5) LD images using a DLE approach trained on MR data ($DLELD_{MR}$). Subjective image quality was evaluated by 4 blinded board-certified readers using a 5-point Likert scale. Quantitative measures of PSNR, SSIM, and NRMSE were compared for the entire image volume and segmented regions of inflamed bowel. A Wilcoxon signed-rank test was used to compare the aforementioned measures with P<0.05 considered as being statistically significant. **Results:** Quantitative measures of full image analysis were significantly superior for $DLELD_{PET}$ PET, while $DLELD_{MR}$ PET was significantly inferior for all three measures during segmented image analysis. For subjective image quality, both $DLELD_{MR}$ and LD PET images were rated non-diagnostic (scores<2). However, $DLELD_{PET}$ and $DLELD_{PET-MR}$ were rated both diagnostic and higher in subjective quality over SOC PET (scores=3.9, 4.0, versus 3.7, respectively; p<0.05). **Conclusion:** DLELD PET can generate improved quality images from PET studies with a factor of 10x lower dose (compared to conventional clinical FDG administrations) and yield images comparable to SOC PET in patients with Crohn's disease. **Clinical Relevance:** DLELD PET can generate improved quality images from PET studies with a factor of 10x lower dose (compared to conventional clinical FDG administrations) and yield images comparable to SOC PET in patients with Crohn's disease. The availability of such imaging techniques will potentially allow for more prompt and efficacious treatment of inflammatory lesions potentially leading to less fibrosis, strictures and complications of the disease – markedly improving the quality of life in CD patients.

Background

1. Inflammatory bowel disease (IBD) affects more than 3.1 million people in the United States (1). Crohn's Disease (CD), a type of IBD, is chronic, without a clear etiology, and incurable (2).
   - CD patients are typically young with peak incidence occurring during the 2nd and 4th decades of life (3).
   - Transmural inflammation can occur anywhere in the gastrointestinal tract.
   - Lesions occur in a chronic remitting and relapsing pattern and can lead to serious complications such as strictures, fibrosis and fisulta formation (4).
   - Clinical symptoms include diarrhea, abdominal pain, and rectal bleeding, however, inflammation can occur asymptomatically.

2. Recent evidence that complete mucosal healing is paramount to remission in CD
   - Immunomodulatory medications available, however, all come with potentially serious side effects - goal of treatment is to keep the patient in remission while utilizing the lowest effective dose of medication
   - Disease surveillance post treatment as well as follow-up is crucial as they provide evidence as to the efficacy of the current treatment protocol
   - The ability to follow disease progression is crucial, even in the absence of clinical symptoms
     - Untreated, undetected inflammatory lesions can lead to fibrosis of bowel tissue – this cannot be reversed with medication and must be surgically resected to prevent complications such as strictures and bowel obstruction.
3. Simultaneous PET/MRI has been suggested for imaging in CD
   - Gold standard for CD diagnosis and monitoring of disease has been endoscopy, however, it is invasive, has significant risks and requires extensive preparation. It also is inadequate for investigation below the jejunum and above the terminal ileum.
   - It has been shown that PET/MRI provides greater anatomic detail as well as information regarding extra intestinal manifestations than CT, PET/CT, or MRI alone.
   - It eliminates a significant amount of radiation due to omission of CT (vs PET/CT)
   - However, the FDG-PET tracer still emits radiation which over the course of many scans in a lifetime, could still prove to be harmful
4. Deep Learning (DL), a type of machine learning in which numerous hidden "deep" layers are utilized to identify data representations, has been used increasingly in radiology applications.
   - There have been multiple recent studies in which DL has been used for low dose PET image enhancement and reconstruction.
   - DL has been shown to be to be superior to previous techniques such as image filtering, singular value thresholding and model base iterative for image reconstruction tasks.
   - Architectures such as convolutional neural networks and U-Net have produced excellent results in reconstruction tasks.

Specific Aim

We propose a method which utilizes a U-Net architecture to reconstruct full dose PET/MR studies with administration of only 20% of FDG tracer. The resulting radiation exposure is only 0.42 mSV, similar to an abdominal plain film.

Methods

Twenty patients with established diagnosis of Crohn's Disease were scanned on a Signa PET/MR scanner (GE Healthcare, Waukesha, WI) scanner with 5mCi/70 kg of FDG (50% of the normal clinical FDG dose).

Non-contrast, two-point Dixon water, fat, in-phase and out-phase images (as used for MR-based attenuation correction) were acquired, along with a five-minute PET acquisition of bowels in two stations (**Figure 1**).

Simulated low-dose PET images were reconstructed from list mode data, where the five-minute data were reconstructed into one-minute PET images to simulate a 1mCi/70kg injection (figure 1).

Figure 1. Representative Images

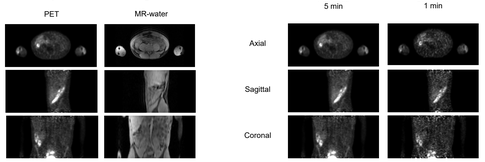

•Deep Learning Model

- A U-Net architecture was implemented comprising of a fully convolutional encoder/decoder (Figure 2).
- Depth = 4, Original # of filters = 64, Batch size = 5, training epoch = 400, 10/5/5 for train/validate/test.
- Three models were trained: PET-only, PET-MR, MR-only
- Data augmentation was performed via rotation, shear, shift, zoom and flip.
- The network was trained utilized the ADAM optimizer until convergence.

Figure 2. Deep Learning U-Net Model Architecture

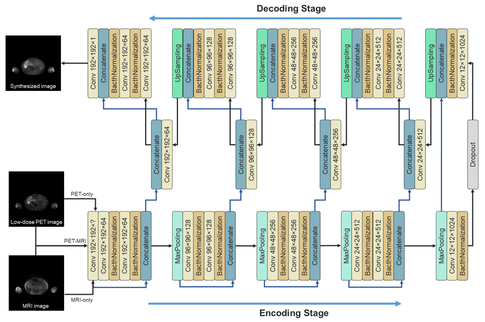

- PET images obtained with using the deep learning approach will be compared to the acquired low-dose and full-dose images
  - Structural Similarity index (SSIM), a method to measure the similarity between two images, was used to quantitatively evaluate the images
  - We also utilized Peak Signal to Noise Ratio (PSNR) and Normalized Root Mean Square Error (NRMSE), another method by which we can quantitatively evaluate the reference from test images.

In addition to quantitative analysis, all subject image sets were evaluated by for diagnostic quality by three board certified abdominal imaging fellowship trained radiologists and a board-certified nuclear medicine physician. A Likert-scale scoring system was used for each reconstruction.

Future Directions

Paired non-parametric statistical tests (Wilcoxon signed-rank test), corrected for multiple comparisons, will be used to compare the subjective (radiologist score) and quantitative scores (image-wise SSIM, image-wise MAPE, and region-wise MAPE) for each low-dose reconstruction relative to alternative low-dose reconstruction methods (BSREM) and the full-dose reconstruction.

Results

The models trained on PET-only and PET-MRI performed well for quantitative metrics of PSNR, SSIM and NRMSE whereas the MRI-only model did not (Table 1, Figure 3).

Table 1. Bold entries indicate measures that are statistically significant (p<0.05) using a paired T-test as measured in the whole body (All) and segmented regions of high uptake in the bowels (Segmented).

		Low Dose	DL PET-only	DL PET-MRI	DL MRI-only
All	PSNR	37.624	**41.142**	**41.299**	**33.882**
	SSIM	0.948	**0.969**	**0.970**	**0.927**
	NRMSE	0.377	**0.245**	**0.240**	**0.541**
Seg	PSNR	50.105	**52.745**	**52.876**	***45.741***
	SSIM	0.998	**0.999**	**0.999**	***0.996***
	NRMSE	0.291	**0.210**	**0.207**	***0.471***

Figure 3. Three - dimensional representation of metrics analysis. PSNR (Peak Signal-to-Noise Ratio), SSIM (Structural Similarity Index), NRMSE (Normalized Root Mean Square Error) are shown via corresponding graphs. Green (PET-MR) and Blue (PET-only) have similar performance. They are both superior to the Red (MR-only) and Grey (Low dose). Slices in the edge of the series have more noise.

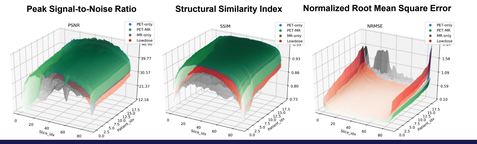

Figure 4: Axial attenuation-corrected PET images with the corresponding average Likert scores by all readers for different image reconstructions, compared to the standard-of-care SOC (A). LD (B) was on average rated as non-diagnostic due to excessive image noise, and $DLELD_{MR}$ (C) was also rated as non-diagnostic is it often failed to show bowel uptake (C, red circle). Conversely, DLR using only the first minute of PET data without or with MR data, respectively $DLELD_{PET}$ (D) and $DLELD_{PET-MR}$ (E), were rated both diagnostic and higher in subjective quality compared to the standard-of-care SOC (A) (all *p* values < 0.05).

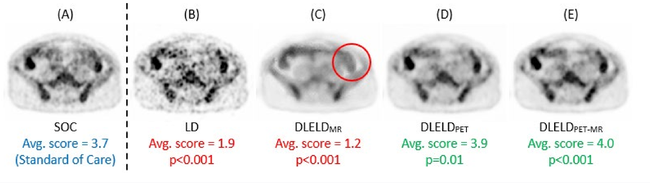

Figure 5. Original Low Dose and Full Dose images juxtaposed to Deep Learning reconstruction images using PET-only, PET-MRI, and MRI-only training data. Pet-only and PET-MRI models retained detailed inflammation signal.

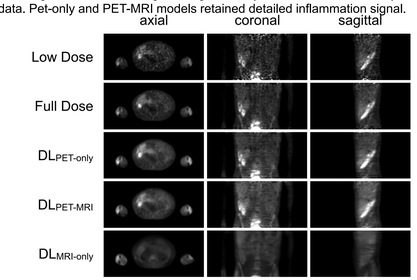

Summary and Conclusions

- Deep learning resulted in an 80% reduction of FDG tracer, while maintaining excellent quality, as quantified by SSIM, NRMSE, and PSNR.
  - Standard CT enterography radiation exposure is approximately 12-20 mSv4 (triphasic up to 63 mSv), whereas our DL method is approximately 0.7 mSv (effective dose from FDG) suggesting a 20-90x potential reduction in ionizing radiation exposure.
- We demonstrated that CNN's have the potential to reduce the radiation exposure of a PET/MRI for CD surveillance towards the level of abdominal plain film radiography.
- MR images do not enhance Deep Learning PET reconstruction synthesis
- Further clinical evaluation of deep learning strategies to reduce radiation dose is highly warranted.
- Ultra low dose PET/MRI utilizing a novel deep learning method will enable surveillance of Crohn's Disease while reducing patients' radiation exposure, ultimately leading to better quality of life for CD patients.

References

1. Ananthakrishnan AN. Epidemiology and risk factors for IBD. Nat Rev Gastroenterol Hepatol [Internet]. 2015 Apr [cited 2018 Mar 30];12(4):205–17. Available from: http://www.nature.com/articles/nrgastro.2015.34

2. Gajendran M, Loganathan P, Catinella AP, Hashash JG. A comprehensive review and update on Crohn's disease. Dis Mon [Internet]. 2018 Feb [cited 2018 Mar 30];64(2):20–57. Available from: http://linkinghub.elsevier.com/retrieve/pii/S0011502917301530

3. Waldner MJ, Rath T, Schürmann S, Bojarski C, Atreya R. Imaging of Mucosal Inflammation: Current Technological Developments, Clinical Implications, and Future Perspectives. Front Immunol [Internet]. 2017 Oct 11 [cited 2018 Mar 30];8. Available from: http://journal.frontiersin.org/article/10.3389/fimmu.2017.01256/full

4. Ram R, Sarver D, Pandey T, Guidry CL, Jambhekar KR. Magnetic resonance enterography: A stepwise interpretation approach and role of imaging in management of adult Crohn's disease. Indian J Radiol Imaging. 2016;26(2):173–84.

Acknowledgements

This study was generously funded in part by the Radiological Society of North America Medical Student Grant and the Department of Radiology at the University of Wisconsin-Madison.