One Across: Temporal Lobe Brain Abscess

Benjamin Chipkin, MS[1] & David Cohen, MD[2]

1. Sidney Kimmel Medical College, Thomas Jefferson University, Philadelphia, PA & 2. ChristianaCare, Newark, DE

INTRODUCTION

- Early recognition of temporal lobe brain abscess prevents life-threatening complications
- Protean manifestations of temporal lobe lesions may delay diagnosis and treatment
- Critical to maintain high degree of suspicion for temporal lobe abscess in eliciting patient history

CASE PRESENTATION

- 73-year-old right-handed retired school teacher with history of chronic otitis media presented with headache and word finding difficulties
- Went to sleep in normal state of health and awoke next morning with throbbing left-sided headache
- Attempted her daily crossword puzzle but could not understand the clues
- Unable to comprehend names of familiar places in conversation with husband
- Receptive aphasia noted on presentation to hospital
- Imaging concerning for left mastoiditis with erosion of tegmen tympani and small (< 2.5 cm) left temporal lobe abscess
- No evidence of seizure on routine electroencephalogram
- Treatment initiated with empiric antibiotics and seizure prophylaxis
- Aphasia and headache resolved on hospital day two
- Remained stable without
- Treatment completed as outpatient without recurrence of symptoms

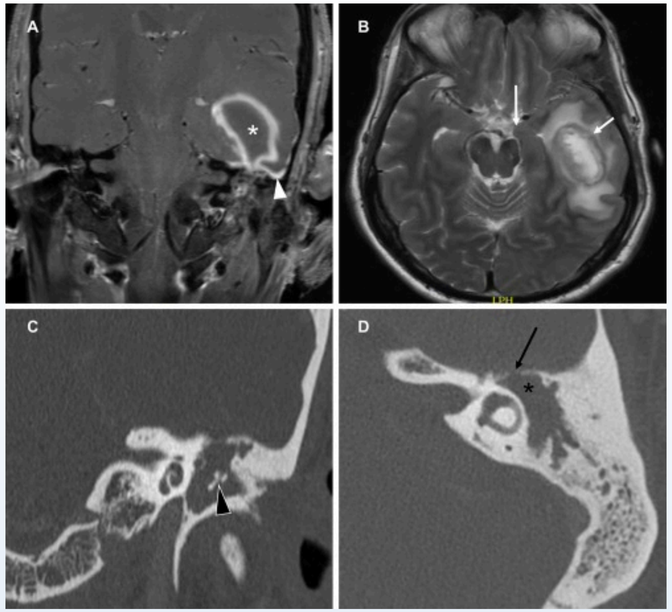

Figure 1. Duarte et al. (2018) published coronal T1 MRI **(A)** showing lesion in left temporal lobe (white asterisk) with adjacent enhancement of dura (white arrowhead). Axial T2 MRI (B) with hypointensity (small white arrow) surrounding lesion. Coronal CT scan **(C)** revealed soft tissue mass in left middle ear and mastoid eroding ossicles (black arrowhead). Axial CT scan **(D)** with erosion of tegmen (black arrow).

Reference: Duarte, M. J., Kozin, E. D., Barshak, M. B., Reinshagen, K., Knoll, R. M., Abdullah, K. G., Welling, D. B., & Jung, D. H. (2018). Otogenic brain abscesses: A systematic review. *Laryngoscope investigative otolaryngology*, *3*(3), 198–208.

DISCUSSION

- Incidence of brain abscesses from direct spread of otologic sources has decreased in developed nations
- Historically, more than 50% of brain abscesses thought to be otogenic
- Prudent use of antibiotics and imaging studies, as well as advances in surgical techniques, led to improvements in outcomes for brain abscesses
- Prompt recognition of brain abscesses remains critical to avoid disease progression
- Heterogenous presentations of temporal lobe lesions include:
  - Difficulty recognizing and interpreting sounds
  - Impaired depth perception
  - Language comprehension deficits
  - Impaired long-term memory retrieval
  - Personality changes
- Small abscesses (< 2.5 cm) identified before expansion can be managed with medical therapy alone, avoiding risks of needle aspiration or surgical excision

CONCLUSION

- Classic case of temporal lobe brain abscess, presenting with patient's inability to complete her daily crossword puzzle
- Highlights the importance of careful history taking for prompt recognition of temporal lobe abscess